

**House Select Committee on Assassinations (HSCA)**

**HSCA Appendix to Hearings - Volume VII**

**Section V. Report of the Forensic Pathology Panel**

**Part III. Observations and Conclusions Derived from the Examination of the Available Evidence...**

**Description of President Kennedy's Wounds**

*Excerpts with emphasis added — followed by actual pages from HSCA report.*

(PAGE 113) **4. Autopsy Report**

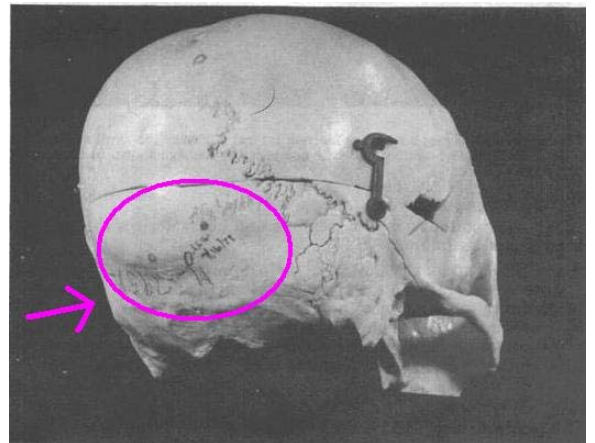
The autopsy report localizes and characterizes the posterior head wound as follows:

Situated in the posterior scalp approximately 2.5 centimeters laterally to the right and slightly above the external occipital protuberance is a lacerated wound measuring 15 x 6 millimeters. In the underlying bone is a corresponding wound through the skull which exhibits beveling of the margins of the bone then viewed from the inner aspect of the skull.

Dr. Finck, in his correspondence to Brigadier General Blumberg, made this observation concerning the entrance wound:

I also noticed another scalp wound, possibly of entrance, in the right occipital region, lacerated and transversal, 15 by 6 millimeters.

Corresponding to that wound, the skull shows a portion of a crater, the beveling of which is obvious on the internal aspect of the bone; on that basis, I told the prosecutors and Admiral Galloway that this occipital wound is a wound of entrance.



(PAGE 114) The panel .... sought to clarify this discrepancy by interviewing three pathologists, Drs. Humes, Boswell, and Finck, and the radiologist, Dr. Ebersole. Each was asked individually to localize the wound of entrance ...Each physician persisted in this localization, notwithstanding the apparent discrepancy between that localization and the wound characterized by the panel members as a typical entrance wound in the more superior "cowlick" area.

(PAGE 115) The panel continued to be concerned about the persistent disparity between its findings and those of the autopsy pathologists and the rigid tenacity with which the prosecutors maintained that the entrance wound was at or near the external occipital protuberance.

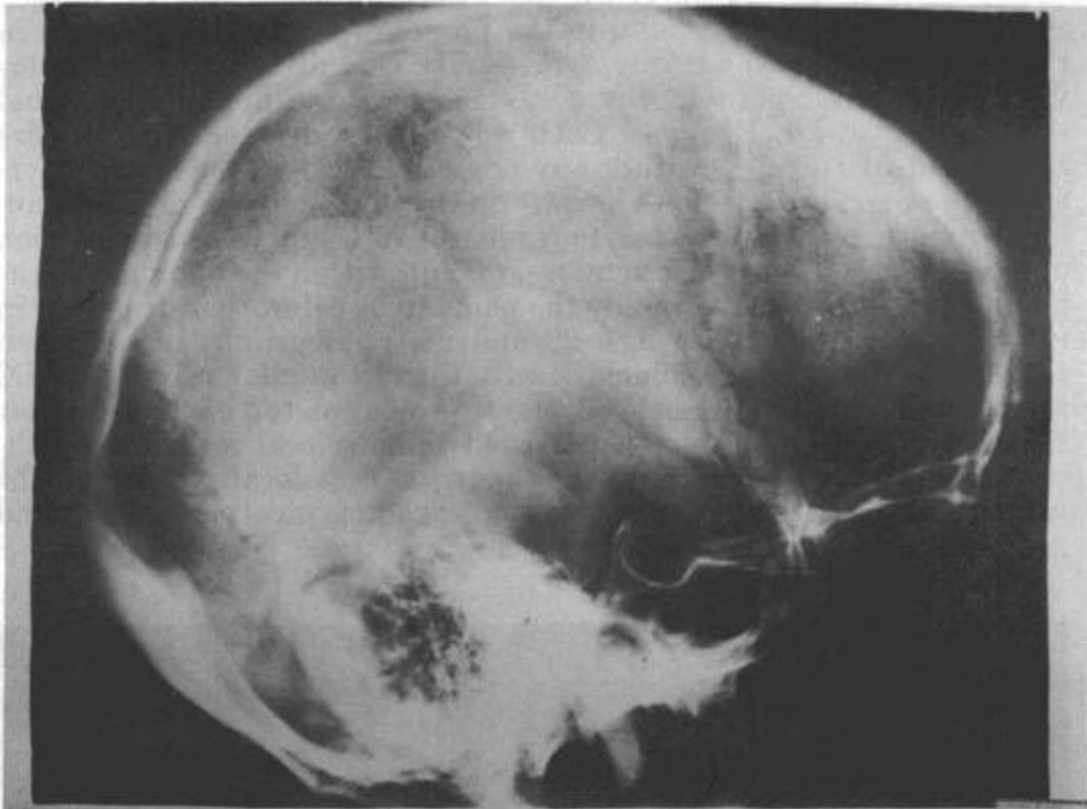


FIGURE 21.—Photograph of a pre-mortem lateral X-ray of the skull of President John F. Kennedy, against which to compare the damage shown in the autopsy X-rays Nos. 1 and 2.

#### 4. Autopsy Report

(304) The autopsy report localizes and characterizes the posterior head wound as follows:

Situated in the posterior scalp approximately 2.5 centimeters laterally to the right and slightly above the external occipital protuberance\* is a lacerated wound measuring 15 x 6 millimeters. In the underlying bone is a corresponding wound through the skull which exhibits beveling\* of the margins of the bone when viewed from the inner aspect of the skull. (34)

The "Autopsy Descriptive Sheet" shows a round circle overlying the occipital protuberance,\* with an arrow extending superiorly and to the left at approximately 11 o'clock and the notation "ragged, slanting, 15 by 6 millimeters." (See fig. 6.) Conspicuous by its absence is any descriptive legend which localizes this wound relative to body landmarks.

(305) Dr. Finck, in his correspondence to Brigadier General Blumberg, made this observation concerning the entrance wound:

I also noticed another scalp wound, possibly of entrance, in the right occipital region, lacerated and transversal, 15 by 6 millimeters. Corresponding to that wound, the skull shows a portion of a crater, the beveling\* of which is obvious on the internal aspect of the bone; on that basis, I told the prosecutors and Admiral Galloway that this occipital wound is a wound of entrance. (35)

(306) The panel was concerned about the apparent disparity between the localization of the wound in the photographs and X-rays and in the autopsy report, and sought to clarify this discrepancy by interviewing the three pathologists, Drs. Humes, Boswell, and Finck, and the radiologist, Dr. Ebersole. Each was asked individually to localize the wound of entrance within any one of several of the above-referenced photographs after reviewing the photographs, X-rays and autopsy report. In each instance, they identified the approximate location of the entrance wound on a human skull and within the photographs as being in a position perceived by the panel to be below that described in the autopsy report. (See figs. 22 and 23, photographs of a human skull.) They also said it coincided with the rectangular white material interpreted by the panel as brain tissue present on top of the hair near the hairline. Each physician persisted in this localization, notwithstanding the apparent discrepancy between that localization and the wound characterized by the panel members as a typical entrance wound in the more superior "cowlick" area.

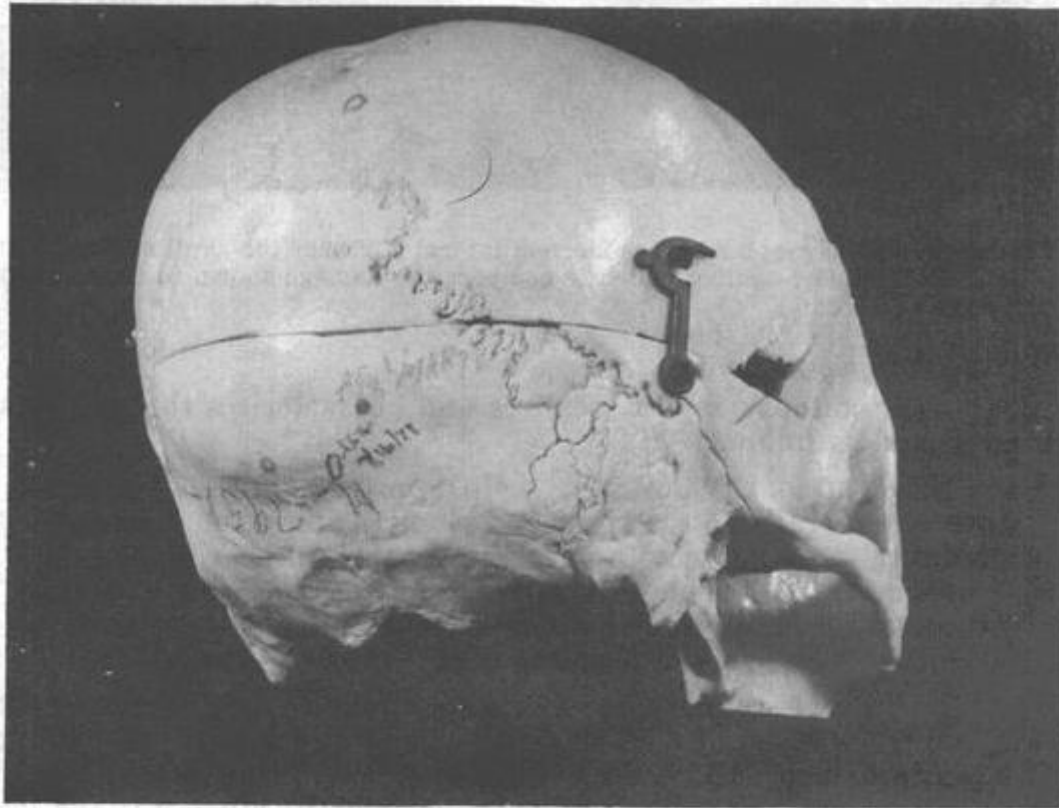


FIGURE 22.—Photograph of the posterior view of a human skull on which the autopsy pathologists, Drs. Humes, Boswell, and Finck, identified the approximate location of the entrance wound. The two initialed circles on the lower portion of the skull and to the right of the midline represent the general area where the autopsy doctors believe the entrance wound to be. (There are two circles because Dr. Finck marked the skull independent of Drs. Humes and Boswell, and without knowing where Drs. Humes and Boswell had placed their circle.) The circle on the top portion of the skull and to the right of the midline represents the general area where the forensic pathology panel believes the entrance to be. (The fourth circle on the lower portion of the skull and approximately on the midline represents the location of the external occipital protuberance.)

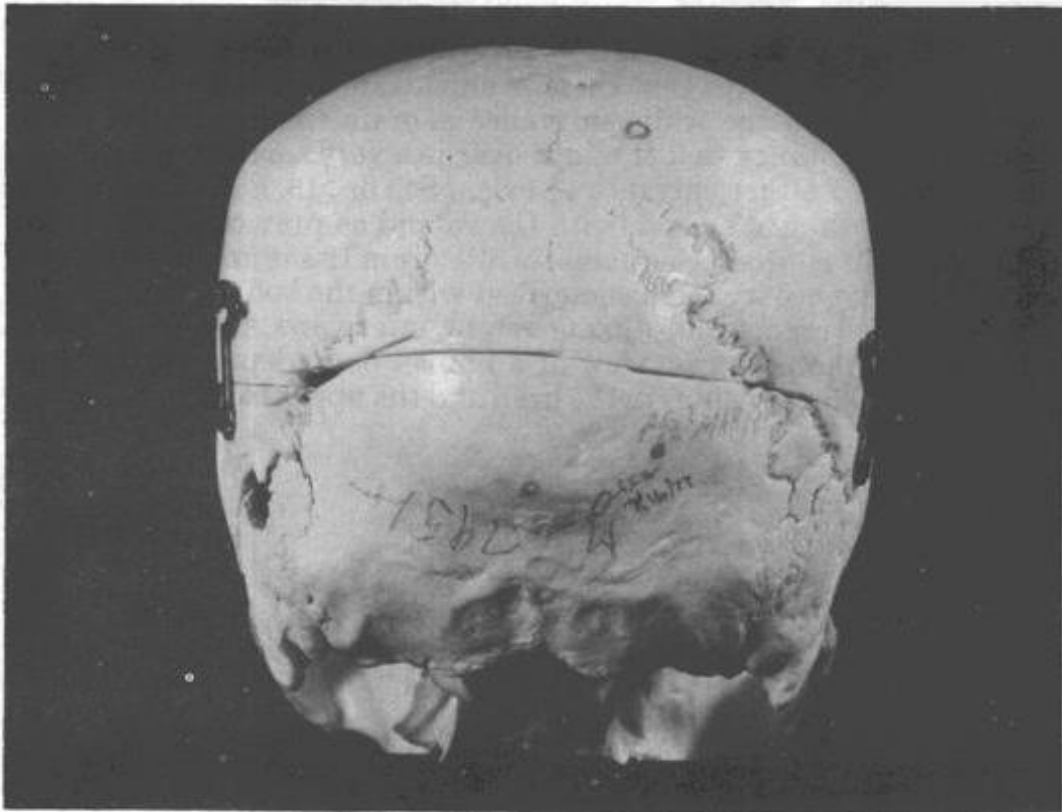

FIGURE 23.—Photograph of the posterior-lateral view of the skull on which the autopsy pathologists identified the approximate location of the entrance wound. (See caption fig. 22.)

(307) Drs. Ebersole, Finck, and Boswell offered no explanation for the upper wound, while Dr. Humes first suggested that it might represent an extension of a more anterior scalp laceration, incident to the exit wound, in spite of the fact that within the photograph the margins of the wound appear to be intact around the entire circumference. Dr. Finck believed strongly that the observations of the autopsy pathologist were more valid than those of individuals who might subsequently examine photographs.

(308) The panel continued to be concerned about the persistent disparity between its findings and those of the autopsy pathologists and the rigid tenacity with which the prosecutors maintained that the entrance wound was at or near the external occipital protuberance.\* Subsequently, however, in his testimony before the select committee, Dr. Humes agreed that the defect was in fact in the "cowlick" area and not in the area of the brain tissue.

(309) The photographs of the brain, described later, also support the panel's conclusions.

(310) One panel member, Dr. Rose, wishes to emphasize the view of the majority of the panel (all except Dr. Wecht) that the absence of injury on the inferior surface of the brain offers incontrovertible evidence that the wound in the President's head is not in the location described in the autopsy report.

(311) All members of the panel except Dr. Wecht concur that there is one and only one wound of entrance in the head and that it is located

in the "cowlick" area of the back of the head, and that the white substance referred to by the original prosecutors is a fragment of brain tissue. Dr. Wecht agrees that there is an entrance wound in the "cowlick" area and that the white substance is brain tissue, but he cannot exclude the possibility that it might overlie a very small skin and bone perforation of either entrance or exit. (See fig. 13, a drawing of the back of the President's head, with the wound as previously identified by the panel. It shows the adherent white brain tissue and the localization of the entrance wound as described within the body of the pathologists' autopsy report and during recent interviews. See also fig. 24, a drawing of the posterior view of a human body depicting the location of the entrance wounds in the head and the upper back.)